

Original Article

The Outcomes of Anterior Spinal Fusion for Cervical Compressive Myelopathy—A Retrospective Review

壓迫性脊髓型頸椎病之前路手術治療效果的回顧分析

Suen Tsz-King*, Wong Kwok-Ho, Ho Yuen-Fong

Department of Orthopaedics and Traumatology, Caritas Medical Centre, Kowloon, Hong Kong

ARTICLE INFO

Article history:

Accepted September 2010

Keywords:

anterior spinal fusion
cervical myelopathy
prognostic factors

ABSTRACT

Background: This study examined the prognostic factors that affect the surgical outcome of anterior spinal fusion in patients with cervical compressive myelopathy (CCM).

Methods: A retrospective review of the result of surgical treatment in 49 cases of CCM using anterior spinal fusion surgical techniques. The study period was from June 1990 to June 2008, with a mean follow-up of 6.57 years. Seven patients died during the follow-up period because of other medical diseases. The Japanese Orthopaedic Association score for cervical myelopathy and recovery rate were used to assess the functional results of the remaining 42 cases.

Results: A mean Japanese Orthopaedic Association score improvement from 10.21 to 14.23 points after the operation was observed. The overall recovery rate was 65.38%, with excellent or good results of 80%. After a year of follow-up, we did not find significant improvement or deterioration on the neurological status on further follow-up. Acute complications were not common. One patient underwent re-operation because of slipping of the graft during resuscitation after early post-operative acute myocardial infarction. This patient showed post-operative neurological deterioration. Two patients had subsidence of the graft, three had pseudo-arthritis, and two had graft resorption. There were also three patients with degenerative changes of the adjacent vertebra. No re-operation was done for patients with these late complications in this review.

Conclusion: Anterior cervical decompression with bone fusion is a viable surgical option for patients with one level of anterior cervical cord compression, especially for patients with kyphosis or straight canal spine. For patients with two- to three-level involvement, anterior cervical decompression with bone fusion provides good functional result in proper selection of cases. We also identified some prognostic factors (male sex, symptoms less than 1 year, and age less than 70 years) in predicting a favourable outcome of anterior spinal fusion for CCM.

中文摘要

背景: 本研究探索經前路手術(ASF)處理頸椎壓迫性脊髓病 (Cervical Compressive Myelopathy) 的一些影響手術結果之預後因素

方法: 本研究回被包括1990-2008年間曾採用盆骨移植前路手術(ASF)處理頸椎壓迫性脊髓病 (Cervical Compressive Myelopathy) 病例共49宗, 平均隨訪時間約6年半。當中七名病人在研究期間因其他內科疾病去世。其餘42名病人在手術前後採用日本骨科學會的頸椎脊髓病評分方法(JOA score)評估功能復原結果。

結果: 術後的平均JOA score評分由10.21改善到14.23分, 平均復原率為65.38%, 百分之八十病人有良好或以上功能之復原。手術一年後隨訪, 病人的神經的功能已經沒有顯著改變。手術後初期引致急性的併發症並不常見。只有一名病人因急性心肌梗塞需要心肺復甦術而引致在術後盆骨移植移位而要重做手術, 她是唯一術後功能比手術前差的個案。在隨訪其間, 骨融合不完全而引至假關節及附近頸椎有提早退化跡象各有三例, 另外有骨移植吸收及下陷各有兩例, 但沒有病人因以上延遲的併發症需要再做手術。

總結: ASF適用於一節段頸椎前路脊髓受壓的病人, 尤其是患者有頸椎後凸畸形或直的頸椎管, 是其中一種可行的手術。患者有兩或三節段頸椎脊髓受壓時, 術後亦有良好的功能性復原, 但需要經過適當地選擇個案。我們亦發現一些影響手術結果之預後因素, 如男性、70歲以下及病徵1年以內的病人會有較佳的復原。

* Corresponding author. E-mail: aarsuen@gmail.com.

Introduction

Cervical compressive myelopathy (CCM) is a spinal cord dysfunction as a result of a slow and gradual mechanical compression and vascular compromise. Patients with underlying spinal stenosis may deteriorate rapidly after acute neck injury. In general, operation should be considered when the patients have marked disturbance of activities of daily living and walking gait. The recommended treatment was cervical spinal cord decompression preserving spinal stability and mobility. The choices of operations include laminoplasty and anterior cervical decompression with bone fusion (ASF) depending on the causes, extension, direction of compression, presence of neck pain, and surgeons' experience.^{1,2}

The effectiveness of using laminoplasty in the treatment of multilevel cervical stenosis is well described in the literature.^{3,4} ASF was suggested for patients with more localised cervical disc degeneration and for patients with spinal kyphosis. Some surgeons used spinal plating at the same operations to achieve immediate stability and to improve the fusion rate. However, this additional procedure may increase the operation time and complications of the implants.

In the literature, some^{5,6} reported less favourable outcomes in elderly patients with history of preceding trauma and long duration of prominent neurological signs.⁷ Other unfavourable factors identified in the patients included lower radiological Pavlov ratio (PR), lower cord compression ratio (CCR), and T2 cord signal changes in magnetic resonance imaging (MRI).⁸

The exact incidence of CCM is unknown in Hong Kong. There were very few reports related to the surgical outcomes of the local Chinese patients. The objective of this study was to review the operative results of the patients in our hospital and to evaluate the prognostic factors that are applicable to our local community.

Materials and Methods

From 1990 to 2008, there were 49 consecutive patients with CCM who had ASF operations done in our department. Seven patients died from unrelated causes during follow-up. Thus, a total of 42 patients were recruited for the study. ASF was limited to those with three or less levels of involvement. We did not use internal fixation in all cases.

Surgical technique

The Smith-Robinson approach⁹ was used. The right neck surgical approach was used in all the cases. The exact spinal segments were determined using intra-operative radiographs. Disectomy with partial corpectomy was done for single-level disc disease. Subtotal corpectomy was performed when two adjacent degenerative discs had to be tackled. Excision of posterior longitudinal ligament was not routinely performed. ASF was done using a tri-cortical bone graft taken from the iliac crest. Internal fixation using plating was not done in our series.

Philadelphia neck collar was applied after the operation for single-level operation. For cases with two or three levels of bone fusions done, a halo-vest was used for 2–4 weeks before changing to a semi-rigid neck collar. Normally, the neck collar will be worn till bone fusion occurred at 8–12 weeks.

Assessment

The functional results of the operation were assessed using the CCM scoring system proposed by the Japanese Orthopaedics

Association (JOA).¹⁰ The functional improvement was expressed by the recovery rate percentage (RR%) as adopted by the JOA, and the final results were rated as excellent, good, fair, unchanged, and worsen, shown as follows:

1. $RR\% = \frac{\text{post-score} - \text{pre-score}}{\text{pre-score}} \times 100\%$
2. Functional result basing on RR%:
Excellent, from 75% to 100%
Good, from 50% to 74%
Fair, from 25% to 49%
Unchanged, from 0% to 24%
Worsen, less than 0%.

The patient sex, age, trauma history, symptom duration, and severity of the neurological signs were analysed. All the abnormal neurological signs detected clinically were classified into early or late signs using the criteria shown in Table 1.

The pre- and post-operative PR, the CCR, and signal change in the T2 image of MRI were also recorded. All the results were analysed using the Pearson correlation and χ^2 test.

Results

From July 1990 to June 2008, 42 patients with ASF operation done were included in the study, and their results are shown in Table 2. The mean follow-up was 6.57 years (range, 10 months to 18 years). The average patient age was 56.45 ± 15.11 years (range, 28–86 years). The sex ratio of male to female was 30:12.

The causes of CCM were disc prolapse (15), spondylosis (26), and ossification of posterior longitudinal ligament (1). The levels were affected in the frequency of C5/6 (31), C4/5 (24), C3/4 (15), C6/7 (10), and C2/3 (2) spinal segments.

No patient required combined approach. The ASF was of one level in nine cases, two levels in 26 cases, and three levels in seven cases. The average level of involvement was 1.95 ± 0.62 .

Concomitant spinal disorders and other joint diseases were not uncommon; eight patients had associated lumbar spinal stenosis, and among them, three had an operation done sometime earlier. There were three patients with history of stroke and five with prostatism.

JOA score

The mean JOA score improved from 10.21 ± 3.49 points to 14.23 ± 2.83 points. The overall RR% was $65.38 \pm 26.36\%$. The JOA functional rating showed 14 cases being excellent, 20 good, 6 fair, 1 unchanged, and 1 worsened. Therefore, 80% of the patients had good or excellent improvement of their symptoms. Their relevant data are illustrated in Table 2.

Prognostic factors

The statistical significances of the different prognostic factors with good to excellent functional results are shown in Table 3. The

Table 1
Summary of early and late myelopathic signs

Early myelopathic signs	Late myelopathic signs
Didiachokinesia	Gross spastic
Fine motor deficits	Gross motor deficits
Mild increase in jerk	Marked increase in jerk
Mild or unsustained clonus	Sustained clonus
Decreased proprioception	Gross difficulty in balance
Difficulty with tandem gait	Difficulty with routine gait
FES Grade 1–2	FES Grade 3–4

Table 2
Data of patients treated with anterior cervical decompression with bone fusion

Case no.	Age (y)	Level	No. of levels	Symptoms >12 mo	Early/late neurology	Pre-op JOA score	Post-op JOA score	RR%	Grade
1	40	C4–6	2	No	Early	16	17	100	Excellent
2	43	C5–6	1	No	Early	12	17	100	Excellent
3	46	C5–7	2	No	Early	14	17	100	Excellent
4	58	C4–6	2	No	Early	12	16	80	Excellent
5	63	C3–4 and C5–6	2	No	Early	7	17	100	Excellent
6	29	C4–5	1	No	Early	12	17	100	Excellent
7	42	C3–4 and C5–6	2	No	Early	15	17	100	Excellent
8	45	C4–5	1	No	Early	15	17	100	Excellent
9	68	C4–6	2	No	Early	12	17	100	Excellent
10	54	C5–7	2	No	Late	12	17	100	Excellent
11	65	C4–7	3	No	Late	10	16	86	Excellent
12	54	C4–6	2	No	Late	10	17	100	Excellent
13	55	C4–5 and C6–7	2	No	Late	12	16	80	Excellent
14	72	C2–3	1	No	Late	12	16	80	Excellent
15	28	C5–6	1	No	Early	11	15	67	Good
16	38	C3–6	3	No	Early	2	10	53	Good
17	52	C5–7	2	No	Early	15	16	50	Good
18	59	C3–4 and C5–6	2	No	Early	11	15	67	Good
19	83	C3–6	3	No	Early	9	13	50	Good
20	73	C3–5	2	Yes	Early	11	14	50	Good
21	42	C3–5 and C6–7	3	No	Late	14	16	67	Good
22	43	C5–6	1	No	Late	6	13	64	Good
23	47	C3–5	2	No	Late	12	15	60	Good
24	50	C4–6	2	No	Late	14	16	67	Good
25	52	C5–6	1	No	Late	8	13	56	Good
26	52	C3–4 and 5–6	2	No	Late	11	15	67	Good
27	59	C3–5	2	No	Late	4	13	69	Good
28	60	C5–7	2	No	Late	8	15	78	Good
29	71	C5–7	2	No	Late	9	14	63	Good
30	32	C5–7	2	Yes	Late	11	14	50	Good
31	45	C4–7	3	No	Late	13	15	50	Good
32	48	C5–6	1	No	Late	13	15	50	Good
33	66	C4–6	2	No	Late	12	15	60	Good
34	47	C4–6	2	Yes	Late	11	14	50	Good
35	63	C3–4	1	No	Early	2	9	47	Fair
36	77	C3–4 and C5–6	2	Yes	Late	8	12	44	Fair
37	57	C3–5	2	Yes	Late	11	13	33	Fair
38	63	C3–5	2	No	Late	8	10	22	Fair
39	77	C4–6	2	Yes	Late	7	11	40	Fair
40	84	C4–7	3	No	Late	5	10	42	Fair
41	83	C4–6	2	No	Late	4	6	15	Unchanged
42	86	C2–4 and C5–6	3	No	Early	8	7	–11	Worsen

JOA = Japanese Orthopaedics Association; Post-op = post-operative; Pre-op = preoperative; RR% = recovery rate percentage.

study demonstrated that better surgical outcomes were seen in patients who were males ($p = 0.018$), had symptoms less than 1 year ($p = 0.001$), and were younger than 70 years ($p = 0.038$).

We did not demonstrate that patients with early myelopathic neurological signs did better after the operation compared with those with late neurological signs. There were no statistically significant findings regarding the preoperative PR, CCR, and signal

changes of the cord in the MRI. Considering the PR less than 0.8, 76% (32 of 42) of our patients had cervical spinal stenosis.

Complications

Early

There were two cases of superficial wound infection and one case of transient vocal cord paralysis. There was no formation of haematoma, spinal cord injury, air embolism, deep vein thrombosis, and injury to the other neck structures. Re-operation was done in one case because of slipping of the graft during resuscitation for early post-operative acute myocardial infarction. The patient had deterioration in general condition accompanied with mental confusion and deterioration in JOA score with RR% being 11%.

Late

Two patients had subsidence of the graft, three had pseudoarthrosis from non-union, and two had graft resorption resulting in kyphosis of 5–10°. There were also three cases with degenerative changes of the adjacent vertebra. However, no revision surgery was done because the patients were asymptomatic.

Table 3
Analysis of factors in patients with good to excellent functional results

Factors (a vs. b)	Odds ratio	Correlation value	<i>p</i>
Gender (male vs. female)	6.427	0.364	0.018*
Age (greater than vs. less than 70 y)	0.08	–0.486	0.001†
Symptoms (greater than vs. less than 1 y)	0.161	–0.322	0.038*
With vs. without trauma history	0.290	–0.196	0.213
Neurology signs (early vs. late)	2.368	0.153	0.334
Pavlov's ratio (less than vs. greater than 0.8)	0.397	–0.129	0.416
With or without T2 signal changes	1.429	0.070	0.660
Cord compression ratio (less than vs. greater than 0.4)	0.697	–0.062	0.694

Odds ratios with good to excellent functional results while comparing factor a with factor b.

* Correlation is significant at the 0.05 level (two tailed).

† Correlation is significant at the 0.01 level (two tailed).

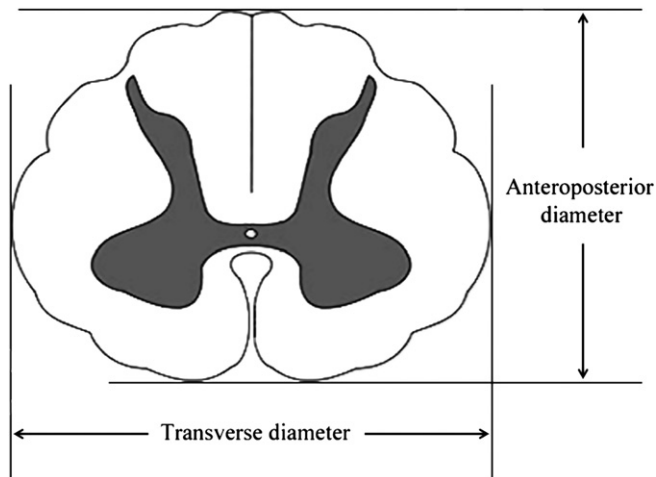


Figure 1. Cord compression ratio using magnetic resonance imaging: anteroposterior and transverse diameters.

Discussion

The operative treatment for CCM reverts the neurological compression of the spinal cord. Both the posterior and anterior spinal operations have been advocated.^{2,11} ASF is the method of choice for CCM because of anterior compression with less than three levels' involvement³ and in cases with kyphotic spinal deformity.

The results of operation for CCM in our study were encouraging. There was only one case with poor result because of post-operative myocardial infarction. Although some patients had graft resorption, pseudoarthrosis, and degenerative changes of the adjacent spinal segment,¹² none of them caused significant disability in long term.

The mean RR% for the ASF group in our study was 65.38%, with an average of 4 points gained in the JOA score. Eighty percent of our patients had achieved a good or excellent functional result. The study also demonstrated that better surgical outcomes were seen in patients who were males ($p = 0.018$), had symptoms for less than 1 year ($p = 0.001$), and were younger than 70 years ($p = 0.038$).

In contrast to other studies that did not demonstrate significant correlation with gender,¹³ more studies are required to verify the result. Advanced age gave an unfavourable prognostic result because it may be related to the more complicated degenerative changes or associated comorbidities in the elderly.^{5,6}

Our study was in accordance with other reports¹⁴ that patients with less than a 1-year duration of symptoms showed significantly greater motor recovery. This could be accounted for by prolonged compression of spinal cord that resulted in irreversible histological and physical changes of the neural structures, such as intraneural fibrosis, demyelination, and death of neurons.

The other prognostic factors, such as PR, CCR, and MRI T2 signal changes, showed no statistical significance in our study. This may be attributed to various reasons.

X-ray PR may be a crude method with significant inter-observer variation. The changes in CCR may be the result of both the anteroposterior and transverse diameters being reduced; especially in severe compression, the calculated CCR will be affected (Figure 1). The exact transverse area of spinal cord at maximum compression may give a better estimate.¹⁵ In addition, signal change in T2 image in MRI is because of cord ischaemia secondary to spinal stenosis.^{14,16} These lesions progress further to cystic necrosis and a secondary syrinx within the atrophied spinal cord, which signifies

irreversible pathological degeneration in grey matter. However, a hyperintense area on T2-weighted images may also reflect reversible oedema formation and secondary cord compression.¹³ These may explain why we could not demonstrate it to be a prognostic factor in our study.

Conclusions

ASF is a viable surgical option for patients with one level of anterior cervical cord compression, especially for those with kyphosis or straight canal spine. For patients with two to three levels' involvement, ASF will provide good functional result in proper selection of cases, that is, patients with PR greater than 0.8 and significant compression with huge prolapsed or sequestered disc preferable to be removed from the anterior route. We also identified the prognostic factors (male sex, symptoms less than 1 year, and age less than 70 years) in predicting favourable outcome of anterior spinal fusion.

Acknowledgement

Disclaimer: The authors did not receive grants or outside funding in support of their research for or the preparation of this manuscript. They did not receive payments, other benefits, commitment, or agreement to provide such benefits from a commercial entity.

References

- Sakaura H, Hosono N, Mukai Y, et al. Long-term outcome of laminoplasty for cervical myelopathy due to disc herniation: a comparative study of laminoplasty and anterior spinal fusion. *Spine* 2005;**30**:756–9.
- Rao RD, Gourab K, David KS. Operative treatment of cervical spondylotic myelopathy. *J Bone Joint Surg Am* 2006;**88**:1619–40.
- Kawakami M, Tamaki T, Iwasaki H, et al. A comparative study of surgical approaches for cervical compressive myelopathy. *Clin Orthop Relat Res* 2000;**381**:129–36.
- Chiba K, Toyama Y, Watanabe M, et al. Impact of longitudinal distance of the cervical spine on the results of expansive open-door laminoplasty. *Spine* 2000;**25**:2893–8.
- Fujiwara K, Yonenobu K, Ebara S, et al. The prognosis of surgery for cervical compression myelopathy. *J Bone Joint Surg Br* 1989;**71B**:393–8.
- Epstein JA, Janin Y, Carras R, et al. A comparative study of the treatment of cervical spondylotic myelopathy. Experience with 50 cases treated by means of extensive laminectomy, foraminotomy, and excision of osteophytes during the past 10 years. *Acta Neurochir (Wien)* 1982;**61**:81–104.
- Tanaka J, Seki N, Tokimura F, et al. Operative results of canal-expansive laminoplasty for cervical spondylotic myelopathy in elderly patients. *Spine* 1999;**24**:2308–12.
- Matsuda Y, Miyazaki K, Tada K, et al. Increased MR signal intensity due to cervical myelopathy. Analysis of 29 surgical cases. *J Neurosurg* 1991;**74**:887–92.
- Robinson RA, Smith GW. Anterolateral cervical disc removal and interbody fusion for cervical disc syndrome. *Bull Johns Hopkins Hosp* 1955;**96**:223–4.
- Hirabayashi K, Miyakawa Y, Satomi K. Operative results and postoperative progression of ossification among patients with ossification of cervical posterior longitudinal ligaments. *Spine* 1981;**6**:354–64.
- Wada E, Suzuki S, Kanazawa A, et al. Subtotal corpectomy versus laminoplasty for multilevel cervical spondylotic myelopathy: a long-term follow-up study over 10 years. *Spine* 2001;**26**:1443–8.
- Hilibrand AS, Carlson GD, Palumbo MA, et al. Radiculopathy and myelopathy at segments adjacent to the site of a previous anterior cervical arthrodesis. *J Bone Joint Surg Am* 1999;**81**:519–28.
- Kohno K, Kumon Y, Oka Y, et al. Evaluation of prognostic factors following expansive laminoplasty for cervical spinal stenotic myelopathy. *Surg Neurol* 1997;**48**(3):237–45.
- Suri A, Chhabra RP, Mehta VS, et al. Effect of intramedullary signal changes on the surgical outcome of patients with cervical spondylotic myelopathy. *Spine* 2003;**3**:33–45.
- Okada Y, Ikata T, Yamada H, et al. Magnetic resonance imaging study on the results of surgery for cervical compression myelopathy. *Spine* 1993;**18**:2024–9.
- Quencer RM, Sheldon JJ, Post MJ, et al. MRI of the chronically injured cervical spinal cord B. *Am J Roentgenol* 1986;**147**:125–32.