



Contents lists available at [ScienceDirect](#)

# Journal of Orthopaedics, Trauma and Rehabilitation

Journal homepages: [www.e-jotr.com](http://www.e-jotr.com) & [www.ejotr.org](http://www.ejotr.org)



## Research Study

# Experience with the Distally Based Sural Neurocutaneous Flap for Ankle and Heel Wounds



## 遠端蒂腓腸神經營養血管皮瓣應用在足踝部和腳後跟的傷口的經驗

Kwok Sin-To\*, Chan Wing-Leung, Lau Yan-Kit

Department of Orthopaedics and Traumatology, United Christian Hospital, Kowloon, Hong Kong Special Administrative Region

### ARTICLE INFO

#### Article history:

Received 12 May 2015  
Received in revised form  
18 September 2015  
Accepted 3 October 2015

#### Keywords:

sural nerve  
surgical flap  
wounds

### ABSTRACT

**Background/Purpose:** Soft tissue loss over the ankle and heel is a challenging issue for reconstructive surgeons. The aim of this study is to present the technique of using sural neurocutaneous flap and analyse the results.

**Methods:** From 2002 to 2014, 15 cases of sural flap were performed in the Department of Orthopaedics and Traumatology of United Christian Hospital, Hong Kong. All cases were handled by two hand surgeons. The outcomes and complications were reviewed retrospectively.

**Results:** The aetiology included trauma (6 cases), neoplasm (4 cases), Achilles tendon repair wound complication (3 cases) and ulcer (2 cases). The age of patients ranged from 21 years to 82 years (average, 61.9 years). The size ranged from 12 cm<sup>2</sup> to 99 cm<sup>2</sup>. The mean follow-up period was 20 months. Eleven flaps healed successfully without significant complications.

**Conclusion:** Sural neurocutaneous flap is a reliable flap design with constant vascular anatomy. There is minimal donor site morbidity, and no major vessels are sacrificed. It provides a durable, pain-free, functionally and aesthetically satisfying coverage for ankle and heel wounds.

### 中文摘要

**背景:** 重建在足踝部和腳後跟的軟組織損失,對外科醫生來說,是一個十分富挑戰性的難題。本研究的目的是研究遠端蒂腓腸神經營養血管皮瓣的應用和分析術後結果。

**方法:** 從2002年到2014年,在香港基督教聯合醫院進行了15例遠端蒂腓腸神經營養血管皮瓣手術。所有手術由兩位手外科醫生主理。我們回顧了手術結果和併發症。

**結果:** 15例的病因包括外傷(6),腫瘤(4),跟腱修復手術傷口併發症(3)和潰瘍(2)。病人年齡介乎21至82歲,平均61.9歲。傷口大小介乎12至99平方厘米。平均隨訪期為20個月。當中十一例皮瓣癒合成功,沒有顯著的併發症。

**結論:** 蒂腓腸神經營養血管皮瓣是一種設計可靠而帶有固定血管解剖位置的皮瓣。它的供皮位創傷小,也不需要有大血管被犧牲。它為足踝部和腳後跟傷口提供了一個耐用,無痛苦,功能上和美學上都令人滿意的覆蓋方案。

## Introduction

Soft tissue loss at the level of ankle and heel often presents a challenging problem to orthopaedic surgeons because of the lack of local soft tissue for coverage. It is also usually associated with poor or marginal circulation. Tendons and bones are commonly exposed because of the relatively thin subcutaneous tissue. The functional

demands over this area such as weight bearing and shoe wear warrant a surgical procedure of coverage.

To cover skin defects over lower limbs, various choices can be used from delayed healing to free flaps. Delayed healing and skin graft are not suitable to cover exposed tendon and bone. Skin graft is also difficult to perform with the lack of a well-nourished soft tissue base. The use of local transposition flaps is restricted by their limited size and arc of rotation. Free flap can provide good coverage especially for large defects, but it requires

\* Corresponding author. E-mail: [oscarst@gmail.com](mailto:oscarst@gmail.com).

microvascular expertise, sophisticated equipment, and lengthy procedure.

Fasciocutaneous flaps with distal pedicles have become another useful option in the repair of soft tissue defects of the lower leg. A detailed description of the sural flap anatomy and surgical procedure was given by Masquelet et al<sup>1</sup> in 1992. Its vascular axis is the median superficial sural artery, the accompanying artery of the sural nerve and lesser saphenous vein. The sural flap is based on the distal peroneal septocutaneous perforators. The aim of this study was to evaluate the outcomes of the distally based sural neurocutaneous flap for coverage of ankle and heel wounds.

## Methods

From 2002 to 2014, we performed 15 cases of sural flap on 14 patients in the Department of Orthopaedics and Traumatology of United Christian Hospital (Hong Kong). This is a retrospective case review. We assessed the outcomes and complications as well as risk factors such as aging, diabetes mellitus, and peripheral vascular disease which should not be the contraindications to sural flap. All cases were handled by two hand surgeons.

### Operative technique

The patients were placed in the prone or lateral position. With the guidance of Doppler ultrasound, the lowermost septocutaneous perforator of the peroneal artery was located and marked at ~5 cm proximal to the lateral malleolus. A line was drawn from the mid-popliteal fossa between the two heads of gastrocnemius muscles to the midpoint between the Achilles tendon and the lateral malleolus. It represents the course of the sural nerve and the lesser saphenous vein. The flap skin paddle was also along this line as its central axis. The pedicle length and flap location were designed according to the distance between the planned pivot point and the defect (Figure 1). The design and the size of the flap were determined by the soft tissue defect.

Tourniquet was applied without exsanguination. The proximal margin was dissected first. The deep fascia was incised. The lesser saphenous vein, the sural nerve and the median superficial sural artery were identified and included in the flap (Figure 2). Anchoring stitches were placed to avoid separation of skin and fascia. The flap was elevated from proximally to distally with longitudinal strip of fascia containing the nerve, the vein and the accompanying artery. The skin extension was left over the pedicle. The width of the adipofascial pedicle was ~3 cm, and the pedicle dissection stopped at the pivot point that was at least 5 cm above the lateral malleolus

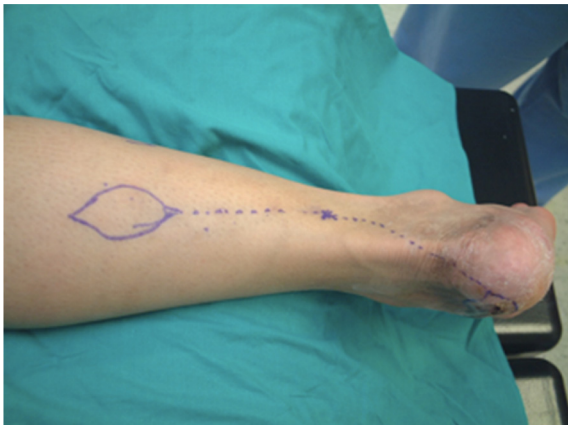

Figure 1. Preoperative planning with pivot point marked.

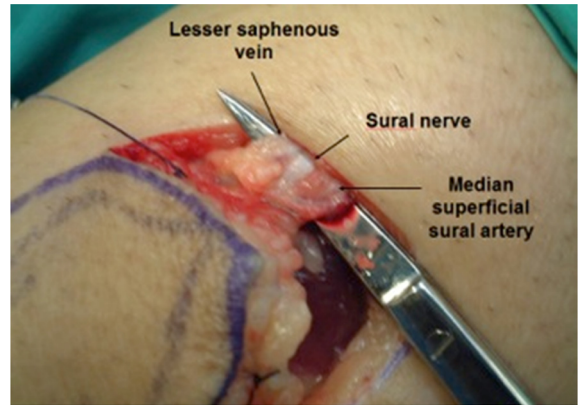


Figure 2. Important structures to be identified during operation.

(Figure 3). We routinely released the tourniquet to check the perfusion of the flap after harvesting it. Bipolar diathermy was used to control all bleedings. We did not reinflate the tourniquet during inseting and the rest of the procedure. The flaps were rotated and passed through a subcutaneous tunnel to cover the defects in the first four cases. In the subsequent 11 cases, the flaps were transposed through an open tunnel with splint thickness skin graft covering the exposed pedicles (Figures 4 and 5).

Postoperatively, a dorsal plaster of Paris slab was applied for 2 weeks to keep the ankle in plantar flexion so as to decrease stretching of the pedicle. The operated leg was elevated without pressure on the vascular pedicle. We also marked “No Pressure” in red on the dressing surface overlying the area of the flap. This helps to remind the nursing staff not to put the foot on the bed or a pillow, which may press onto the pedicle or flap. Dextran 40 infusion (in 500 mL normal saline) over 4 hours daily was given for 3 days. Nonweight bearing was prescribed for 4 weeks in total (Figure 6).

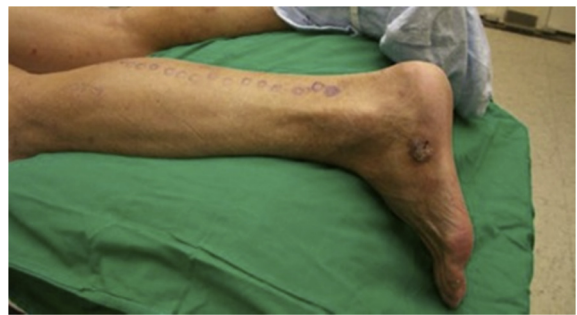

Figure 3. Case of basal cell carcinoma over lateral foot in preoperative planning.

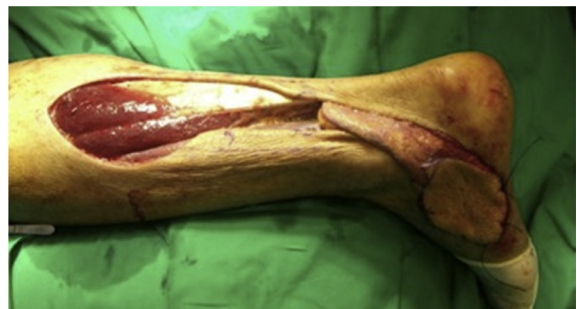
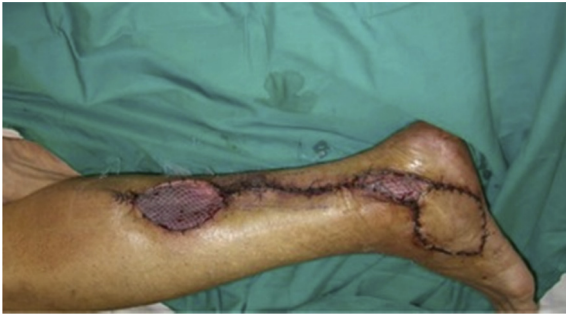
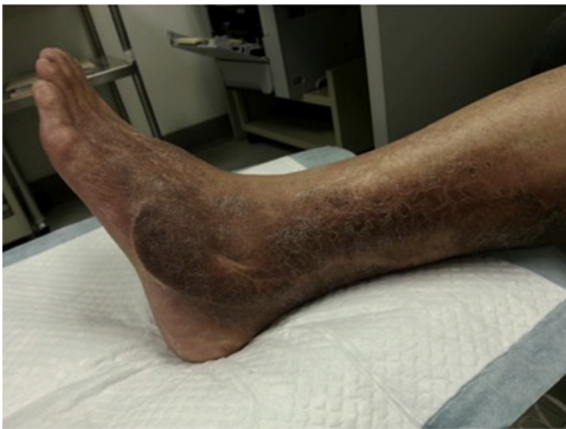Figure 4. Rotating the sural flap in an open tunnel to cover the excised wound defect.



**Figure 5.** After the operation: donor site and the open tunnel covered with partial thickness skin graft.



**Figure 6.** Postoperative 5 years: wound, well healed.

## Results

There were eight males and six females, whose age ranged from 21 years to 82 years (mean age, 61.9 years). The defects were located around the posterior heel in nine cases, medial malleolus in three cases, lateral malleolus in two cases, and heel pad in one case. The aetiology included trauma in six cases, neoplasm in four cases, Achilles tendon repair wound complications in three cases and ulcers in two cases. Four patients had diabetes whereas one patient had peripheral vascular disease. The follow-up time ranged from 5

days to 5 years (mean, 20 months; Table 1). The size ranged from 12 cm<sup>2</sup> to 99 cm<sup>2</sup> (average, 37.2 cm<sup>2</sup>). The largest dimension of defect was 14 cm × 7.1 cm. There was one mortality case (6.7%), a 76-year-old gentleman who suffered from a polytrauma. He had a history of chronic obstructive pulmonary disease, and he was involved in a road traffic accident that resulted in an open fracture of talus and calcaneum. He died on postoperative Day 5 because of severe pneumonia. Two cases (13%) were complicated with methicillin-resistant *Staphylococcus aureus* (MRSA) infection. Both cases presented with MRSA-infected ulcers prior to the sural flap operations. Eventually, above-the-knee amputations were still required in both patients. One case (6.7%) suffered from partial necrosis, which healed by secondary intention. So the remaining 11 flaps healed successfully without significant complications. One patient (6.7%) complained of annoying numbness over the lateral border of the foot after a sural flap procedure. There was no significant donor-site morbidity.

## Discussion

In 1992, Masquelet et al<sup>1</sup> reported the blood supply to the skin from the arteries accompanying the superficial sensory nerves and defined flaps according to the vascular axes of the sural and saphenous nerves. They identified a superficial sural artery arising from the popliteal artery. It follows the course of the sural nerve and then emits numerous branches to the skin at the lower half of the leg along the suprafascial course. Three to five septocutaneous perforators come from the peroneal artery and anastomose with the vascular network of the nerve. These anastomoses are constant.<sup>1</sup> Other clinical series basing on this vascular anatomy also showed that the sural neurocutaneous flap is reliable with many advantages. A relatively large flap can be harvested with little donor-site morbidity. Dissection of the flap is easy with no sacrifice of any major artery, whereas microvascular anastomosis is not required. It can provide a wide arc of rotation over the pivot of the pedicle to cover the defects on heel, ankle, and hindfoot. This fasciocutaneous flap is also durable even on these weight-bearing areas. One of our cases was also successfully managed at the site of the heel pad.

Flap complications were recorded in 26.4% of cases with a flap loss rate of 3.2%.<sup>2</sup> Common complications include sensory loss over the lateral side of the foot and leg, infection, and flap necrosis. Some authors suggested that the sural nerve must not be taken with the flap, whereas others observed flap necrosis in some

**Table 1**  
Summary of patients' data

Case No.	Age (y)	Sex	Aetiology	Site	Size (cm <sup>2</sup> )	Tunnel (close/open)	FU (mo)	Complications	Comorbidities
1	21	M	Trauma	Medial	3 × 5	C	3	Nil	Nil
2	49	F	Trauma	Posterior	5.5 × 4.5	C	3	Nil	Nil
3	65	F	Ulcer	Medial	3 × 6	C	3	MRSA infection	DM/HT/IHD
4	78	F	Trauma	Medial	3 × 4	C	9	Partial necrosis	DM/HT/IHD/CVA
5	82	M	Neoplasm	Lateral	5 × 7	O	60	Nil	HT
6	76	M	Neoplasm	Posterior	4 × 7	O	52	Nil	Nil
7	76	M	Trauma	Posterior	14 × 7.1	O	5 d	Died from pneumonia	COPD/old TB
8	79	F	Neoplasm	Lateral	7 × 4.5	O	36	Nil	DM/HT
9	77	M	Ulcer	Posterior	4 × 6	O	2.5	MRSA infection	DM/HT/IHD/PVD
10	54	M	TA repair wound	Posterior	1 × 2	O	11	Numbness	Nil
11	72	F	Neoplasm	Heel pad	7 × 7	O	27	Nil	Nil
12	29	M	Trauma	Posterior	8 × 12	O	36	Nil	Nil
13	Same	patient	as above	Posterior	6 × 1.1	O	36	Nil	Nil
14	58	M	TA repair wound	Posterior	6 × 6	O	18	Nil	Nil
15	51	F	TA repair wound	Posterior	4 × 4	O	1	Nil	HT/asthma

C = close; COPD = chronic obstructive pulmonary disease; CVA = cerebrovascular accident; DM = diabetes mellitus; HT = hypertension; IHD = ischaemic heart disease; MRSA = methicillin-resistant *Staphylococcus aureus*; O = open; PVD = peripheral vascular disease; TA = tendo Achilles; TB = tuberculosis.

sural nerve-preserving cases.<sup>3</sup> Dissecting off the sural nerve could damage sural flap circulation because of the dense interconnection between the vascular structures and the nerve.<sup>4</sup> Although including the sural nerve in the flap may cause the disturbing sensory loss, an adequate blood supply as well as flap survival are more important to patients with chronic wounds. Hence, in all of our cases we included the sural nerve in the flap, resulting in only one patient who complained of the related numbness. Another concerning reason for partial necrosis is venous congestion. Some measures have been proposed to decrease venous congestion. For the venous drainage, vein valves in the lesser saphenous vein are a significant hindrance for reverse venous flow. To bypass this, the venae comitantes of the accompanying artery of the lesser saphenous vein are considered to be important as they have several anastomoses with it and have weak valve resistance.<sup>5</sup> A wider pedicle of ~3 cm was suggested to include a more extensive network of communicating vessels so as to achieve better venous drainage.<sup>6</sup> In early postoperative period, a dorsal slab was applied to keep the ankle in plantar flexion as in this position, wherein the tension of the vascular pedicle should be minimised. The operated leg was also elevated without any contact pressure on the vascular pedicle to decrease venous congestion. We adopted the above measures in our cases. In our study, the fourth case was complicated with partial necrosis in which the flap was passed through the subcutaneous tunnel. After that, the pedicles were rotated and passed through an open tunnel between the pivot point and the defect in subsequent 11 cases. Skin grafting over the open tunnel was completed in a single operation. No partial necrosis was noticed in these 11 cases. It was believed to prevent pressure on the pedicle, which may affect arterial supply and venous return because of the tight subcutaneous tunnel.<sup>7</sup>

Several studies have also assessed the risk factors or any contraindications, such as age, smoking, peripheral vascular disease, venous insufficiency, and diabetes mellitus, associated with flap complications. One retrospective study in 2009 reviewed 58 cases of reverse sural flap.<sup>8</sup> Significantly higher major and minor complication rates were seen in older patients and patients with a history of smoking, obesity, diabetes, or peripheral arterial disease. Multivariate regression analysis identified smoking as the risk factor most independently associated with any reverse sural flap complication. Also, a systematic review in 2014 analysed 61 papers including 907 patients with the use of distally based sural flap to identify risk factors associated with complications.<sup>2</sup> With multivariate analysis, venous insufficiency and increasing age were identified as independent risk factors for complications. Patients with venous insufficiency had nine times the risk of developing a complication compared to patients without venous insufficiency. In our small pool of patients, some elderly individuals with diabetes

mellitus and other medical comorbidities could still achieve good flap healing. However, two cases of ischaemic ulcer with MRSA infection still required above-the-knee amputation after the flap surgery. This may suggest that sural flap may not be a reliable option for patients with ischaemic or atraumatic ulcers, which are prone to have infection. Sural flap cannot help to control infection. We should control all infections, including MRSA, prior to proceeding to sural flap surgery via repeated radical debridement and proper antibiotic treatment. Further studies should be carried out to review the measures and outcomes for this particular group of patients with a larger case number.

## Conclusion

The distally based sural neurocutaneous flap is a reliable flap with constant vascular anatomy. There is minimal donor-site morbidity, and no major vessels are sacrificed. It provides a durable, pain-free, and functionally and aesthetically satisfying coverage of ankle and heel wounds.

## Conflicts of interest

The authors have no conflicts of interest to declare.

## Funding/support

No funding or other financial support was received for the work described in this article.

## References

- Masquelet AC, Romana MC, Wolf G. Skin island flaps supplied by the vascular axis of the sensitive superficial nerves: anatomic study and clinical experience in the leg. *Plast Reconstr Surg* 1992;**89**:1115.
- de Blacam C, Colakoglu S, Ogunleye AA, et al. Risk factors associated with complications in lower-extremity reconstruction with the distally based sural flap: a systematic review and pooled analysis. *J Plast Reconstr Aesthet Surg* 2014;**67**:607–16.
- Yilmaz M, Karatas O, Barutcu A. The distally based superficial sural artery island flap: clinical experiences and modifications. *Plast Reconstr Surg* 1998;**102**:2358–67.
- Kececi Y, Sir E. Increasing versatility of the distally based sural flap. *J Foot Ankle Surg* 2012;**51**:583–7.
- Torii S, Namiki Y, Mori R. Reverse-flow island flap: clinical report and venous drainage. *Plast Reconstr Surg* 1987;**79**:600–9.
- Ahmed SK, Fung BK, Ip WY, et al. The versatile reverse flow sural artery neurocutaneous flap: a case series and review of literature. *J Orthop Surg* 2008;**3**:15.
- Patel KB, Bartholomew SV, Wong MS, et al. Distally based sural lesser saphenous neuro-veno-adipo-fascial (NVAF) flap for reconstruction in the foot: lessons learned. *Foot Ankle Surg* 2010;**16**:e79–83.
- Parrett BM, Pribaz JJ, Matros E, et al. Risk analysis for the reverse sural fasciocutaneous flap in distal leg reconstruction. *Plast Reconstr Surg* 2009;**123**:1499–504.